

## Comparison of the diagnosis of malaria by microscopy, malaria antigen and QBC in endemic areas of Malaria.

Mr. Vivek Trivedi

PhD Scholar LNCT University . Bhopal, Madhya Pradesh.

Dr. Vijay kumar Ramnani

Professor and Head Department of Microbiology, LN Medical College and Hospital.  
Bhopal, Madhya Pradesh

### ABSTRACT

**Background:** Malaria is a life-threatening disease caused by parasites that are transmitted to people through the bites of infected female Anopheles mosquitoes in numerous endemic areas of India. It is preventable and curable. In 2019, there were an estimated 229 million cases of malaria worldwide.

**Material and method:** 100 samples were included in the study, which further processed for QBC, rapid card (antigen detection test) and peripheral blood smear diagnostic test for diagnosis of malaria.

**Result and observation:** Out of total 100 cases thick smear detected 73 positives compared to 70 by thin smear, 72 by dipstick and 69 by QBC. Thick smear proved to be better than the other methods. While dipstick closely followed thick smear, thin smear and QBC had a back stage in comparison.

**Conclusion:** Thick smear proved to be better than the thin smear methods. QBC (quantitative Buffy coat) and thick smear had the disadvantage of difficulty in species identification.

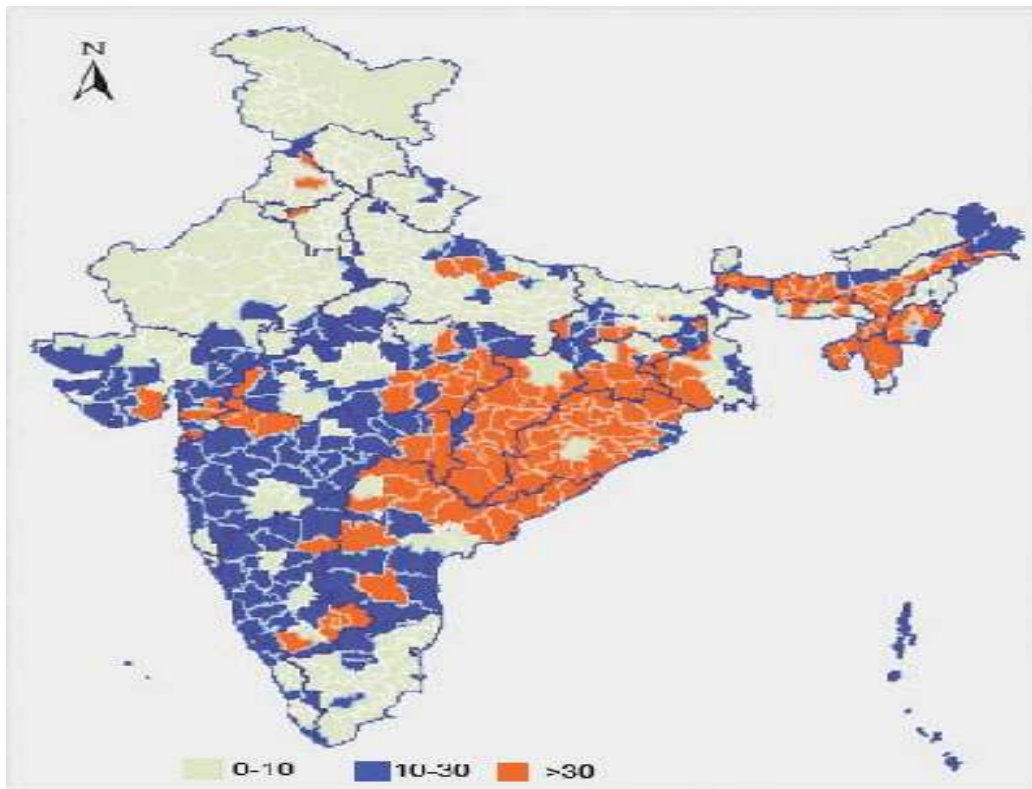
KEYWORDS; PBS, QBC, Dipstick, Malaria

1. **Introduction:** - **Malaria endemic areas in India:** Malaria has been a problem in India for centuries. Details of this disease can be found even in the ancient Indian medical literature like the *Atharva Veda* and *Charaka Samhita*. In the 30's there was no aspect of life in the country that was not affected by malaria. During the latter parts of nineteenth and early twentieth century's, nearly one-fourth of India's population suffered from malaria, particularly in the states like Punjab and Bengal.[1] The economic loss due to the loss of man-days due to malaria was estimated to be at Rs. 10,000 million per year in 1935.

At the time of independence in 1947, of a population of 330 million, about 75 million people were estimated to be infected with malaria every year, and the direct mortality due to the disease was estimated at 0.8 million per annum.[2,3] To combat this menace, the Govt. of India launched the National Malaria Control Programme in April 1953. The programme proved highly successful and the number of malaria cases significantly declined to about 2 million by 1958.[4] Encouraged by this, the programme was changed to a more ambitious National Malaria Eradication Programme in 1958. By 1961 the incidence dropped further to a mere 49151 cases, with no deaths.[5]

- In 2019, there were an estimated 229 million cases of malaria worldwide.
- The estimated number of malaria deaths stood at 409 000 in 2019.
- Children aged under 5 years are the most vulnerable group affected by malaria; in 2019, they accounted for 67% (274 000) of all malaria deaths worldwide.
- The WHO African Region carries a disproportionately high share of the global malaria burden. In 2019, the region was home to 94% of malaria cases and deaths.

Malaria, at one time a rural disease, diversified under the pressure of developments into various ecotypes. These ecotypes have been identified as forest malaria, urban malaria, rural malaria, industrial malaria, border malaria and migration malaria; the latter cutting across boundaries of various epidemiological types. Further, malaria in the 1990s has returned with new features not witnessed during the pre-eradication days. These are the vector resistance to insecticide(s); pronounced exophilic vector behavior; extensive vector breeding grounds created principally by the water resource development projects, urbanization and industrialization; change in parasite formula in favor of *P. falciparum*; resistance in *P. falciparum* to chloroquine and other anti-malarial drugs; and human resistance to chemical control of vectors.[6]



Proportion of *P. falciparum* distribution in India [6]

## 2. Material and method:

**Study design:** The present study is carried out in this institute in 2019-2021.

### **Specimen:**

A total of 100 blood samples of suspected cases of malaria were collected from patients attending the outpatient department and admitted in medical wards.

### **Collection of specimen:**

Capillary blood by finger prick method and/or venous blood collected in the EDTA bulb.

### **Capillary blood method:**

By using sterile technique, the lobe of finger is cleaned using a swab moistened with spirit and the area is allowed to dry. With help of a sterile lancet, the finger is pricked and squeezed gently to obtain enough blood.

### **Venous blood method:**

By using aseptic precautions, tourniquet is tied over the arm. The area of cubital fossa or any other site is cleaned with spirit and allowed to dry. About 2-3 ml of blood is collected in EDTA bulb with the help of 5 ml disposable syringe and 23 mm gauge needle. The bulb is gently shaken to mix the blood with anticoagulant.

Procedure:

Every sample is tested by the following 3 methods:

P/S thin and thick smear.

Dip Stick Malaria—Optimal

QBC capillary method.

**PS for MP:**

Both thin and thick smears are prepared.

Infection of blood from a malaria patient containing the asexual forms of erythrocytic schizogony will also induce malaria in man. This is called trophozoite or macrobiotic induced malaria, which can occur in the following situations. They never initiate a life cycle. They produce direct erythrocytic schizogony.

- i) Transfusion malaria: Transfusion of infected donor blood.
- ii) Malaria in drug addicts: shared syringes among drug addicts when one of them is infected.
- iii) Congenital malaria: very occasionally congenital transmission occurs specially the mother is non-immune

**Thin film field's staining technique:**

1. Place the slide on a staining rack and cover the methanol fixed thin film with approximately 0.5 ml of diluted Field's Stain B.
2. Add immediately an equal volume of Field's stain. A and mix with the diluted Field's stain B. Leave to stain for 1 minute.
3. Wash off the stain with clean water. Wipe the back of the slide clean and place it in a draining rack for the film to air dry.

**3 Results for malaria thin film:**

Chromatin of parasite are appear dark red

Cytoplasm of parasite are appear blue

Schüffner's dots are appear red

Mauer's dots (clefts) are appear red mauve

Malaria pigment in white cells are appear brown black

Red cells are appear grey to pale mauve pink

Reticulocytes are appear grey blue

Nuclei of neutrophils are appear dark purple

Cytoplasm of mononuclear Cells are appear blue gray

Granules of eosinophils are appear red

### **Thick film field's straining technique**

1. Holding the slide with the dried thick film facing downwards, dip the slide in to Field's Stain A for 5 sec. Drain off the excess stain by touching a corner of the slide against the side of the container.
2. Wash gently for about 5seconds in clean water. Drain off the excess water.
3. Dip the slide into Field's Stain B for 3 seconds. Drain off the excess stain.
4. Wash gently in clean water. Wipe the back of the slide clean and place It upright in a draining rack for the film to air dry.

Note: If after staining, the whole of the film appears yellow brown (usually a sign that too much blood has been used), too blue or too pink, do not attempt to examine it. Restrain it. (Dipping in field's stain A for 1 second, field's stain B for 1second).

**Table 1:Results for malaria thick film:**

S.N.	Characteristics of malaria parasite	Color
1.	Chromatin	Dark red
2.	Cytoplasm	blue mauve
3.	Schüffner's dots	Pale red
4.	P.Vivax	Pale red
5.	P.ovale	Pale red
6.	Malaria pigment	Yellow brown or Black brown
7.	Nuclei of small lymphocytes	Dark purple
8.	Nuclei of neutrophils	Dark Purple
9.	Granules of eosinophils	Red
10.	Cytoplasm of mononuclear cells	Blue grey
11.	Reticulum of reticulocytes	blue grey stippling

## 5. Results and observation:

**Table-2:** shows age wise distribution of positive and negative cases of malarial. It shows that the occurrence of malaria is Maximum in 10 – 19, 20 – 29, and 60 and above age in both males and females. Out of 100 patients sampled 20 were in the age group 20-29 years and 19 each in the age group 10 -19 and 60 & above years.

**TABLE – 2**

### AGE WISE DISTRIBUTION OF POSITIVE AND NEGATIVE CASES

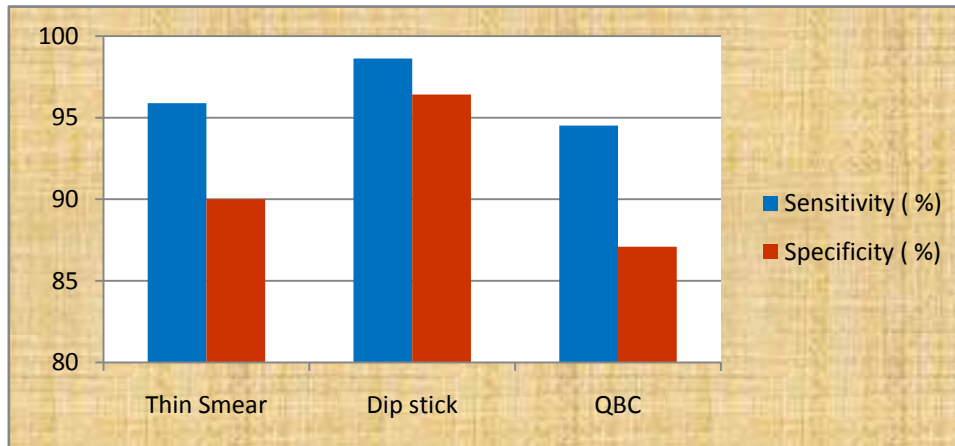
Age	Positive Male	Negative Male	Positive Female	Negative Female	Total Positive	Total Negative
0-9	2	3	1	2	3	5
10-19	7	2	8	2	15	4
20-29	8	3	8	1	16	4
30-39	6	1	3	3	9	4
40-49	4	1	3	3	7	4
50-59	4	2	2	2	6	4
60 AND ABOVE	13	1	5		18	1
<b>Total</b>	<b>44</b>	<b>13</b>	<b>30</b>	<b>13</b>	<b>74</b>	<b>26</b>

**Table 3: Sensitivity and Specificity with respect of Thick Smear**

Test	Thin Smear	Dip stick	QBC
Sensitivity ( %)	95.89	98.63	94.52
Specificity ( %)	90	96.42	87.09

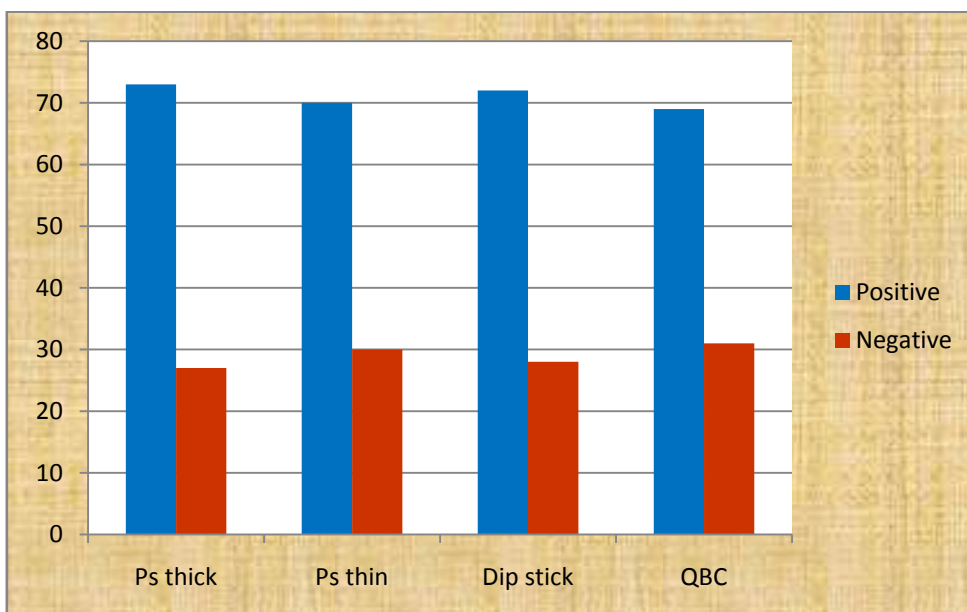
Table 3: shows that with respect to thick smear as the reference test, dip stick enjoys maximum sensitivity (98.63%) and specificity (96.42%) as compared to thin smear and QBC test.

**Chart 1: Column chart showing sensitivity of thin smear, dipstick and QBC w.r.t. thicksmear.**



**Chart 2: Column chart showing positive and negative by different methods**

100 samples were included in the study, which further processed for QBC, rapid card (antigen detection test) and peripheral blood smear diagnostic test for diagnosis of malaria. Out of total 100 cases thick smear detected 73 positives compared to 70 by thin smear, 72 by dipstick and 69 by QBC. Thick smear proved to be better than the other methods. While dipstick closely followed thick smear, thin smear and QBC had a back stage in comparison.



Out of total 100 cases thick smear detected 73 positives compared to 70 by thin smear, 72 by dipstick and 69 by QBC. Thick smear proved to be better than the other methods. While dipstick closely followed thick smear, thin smear and QBC had a back stage in comparison.

## **6. Discussion and conclusion**

The present study and various other studies bring out various facts about diagnosis of malaria. Peripheral smear has stood the test of time and remains the Gold Standard in diagnosis of malaria.

Out of thin and thick smears, thick smear can identify more number of positive cases as larger volume of blood is taken compared to thin smear. Thus its sensitivity is higher than other methods.

Although thick smear has higher sensitivity, inappropriate method can lead to deformation of the morphology of parasite causing difficulty in species identification. Debris and other cellular material can also confuse with rings. Schizonts of *P. vivax* and gametes of *P. falciparum* may deform creating confusion. But if done properly, thick smear is the best method. Field stain consuming lesser time than Giemsa stain is preferable for rapid diagnosis.

Thin smear, as it takes lesser quantity of blood to make, may miss out if parasitemia is low. However a thin smear prepared properly gives a beautiful picture of rings inside RBCs, gametes-male and female and schizonts of *P. vivax*. After all nothing could be as original as seeing the malarial parasite in side its normal habitat i.e .RBC. Dip stick has proved to be a good rapid method which can be used in lieu of peripheral smear in fields for mass survey, in laboratories where technical expertise is not available and to assess response to treatment. The density of colour of positive band is directly proportional to the degree of parasitemia.



**BIBLIOGRAPHY**

1. Monica Cheesbrough (1998) :District Laboratory Practice in Tropical Countries. Part I. 5-7 Examination of blood for Malaria Parasites.p-239.
2. Rajesh Karyakarte, Ajit Damle. Medical Parasitology. Chapter 5,Phylum Apicomplexa, Plasmodium. Plasmodiumsp.p.62.
3. Philippe G, David PJ, Emmanuel B,Lieselotte C, Marjan V Test characteristics of the SD FK80 *Plasmodium falciparum/Plasmodium vivax* malaria rapid diagnostic test in a non-endemic setting *Malaria Journal* 2009, 8:262.
4. Dk mendiratta, k bhutada, r narang, p narang evaluation of different methods for diagnosis of p. Falciparum malaria indian journal of medical microbiology vol. 24, no.
5. Vaidya K, Sukesh, Quantitative buffy coat (qbc) test and other Diagnostic techniques for diagnosing malaria:review of literature national journal of medical research print issn: 2249 4995 | eissn: 2277 8810
- 6 F. Durand<sup>1</sup>, B. Crassous<sup>1</sup>, H. Fricker-Hidalgo<sup>1</sup>, F. Carpentier<sup>2</sup>, J.-P. Brion<sup>3</sup>, R. Grillot<sup>1</sup> and H. Pelloux<sup>1</sup> Performance of the Now Malaria rapid diagnostic test with returned travellers: a 2-year retrospective study in a French teaching hospital *Clin Microbiol Infect* 2005; 11: 903–907
7. n chayani, b das, m sur, s bajoriacomparison of parasite lactate dehydrogenase based Immunochromatographic antigen detection assay (optimal) with microscopy for detection of malaria Parasites indian journal of medical microbiology, (2004) 22 (2):104-106
8. E. Geoffrey playford\* and john walker evaluation of the ict malaria p.f/p.v and the optimal rapid Diagnostic tests for malaria in febrile returned travellers journal of clinical microbiology, nov. 2002, p. 4166–4171 vol. 40, no. 11
9. Anthony Moody\* Rapid Diagnostic Tests for Malaria Parasites clinical microbiology reviews,jan. 2002, p. 66–78 vol. 15, no. 1.
10. Momar n, Etienne B, E kokoskin, w. Gyorkos, J. Dick maclean and brian j.Ward<sup>1</sup> comparison of blood smear, antigen detection, and nested-pcrMethods for screening refugees from regions where malaria is Endemic after a malaria outbreak in quebec, canada journal of clinical microbiology, june 2004, p. 2694–2700 vol. 42, no. 6
11. Lt Col MN Mishra, Surg Capt RN Misra Immunochromatographic Methods in Malaria Diagnosis *MJAFI, Vol. 63, No. 2, 2007*
12. Bhat Sandhya K, Sastry Apurba S , Nagaraj E.R., Sharadadevi Mannur , Sastry Anand S Laboratory diagnosis of malaria by conventional peripheralblood smear examination with

Quantitative Buffy Coat(QBC) and Rapid Diagnostic Tests (RDT) - A comparative study  
International Journal of Collaborative Research on Internal Medicine & Public Health.

13. Dr sangeeta, Bishnoi dr anshu sharma Dr seema Sonkariya a comparative laboratory diagnosis of malaria: microscopy Versus rapid diagnostic test kits volume-9 | issue-3 | march-2020 | print issn no. 2277 - 8179 | doi : 10.36106/ijsr
14. Apparao P, Padmanabam Y, Agrawal PC Prevalence of Malaria from Blood Smears Examination: An Eleven –Year Retrospective Study from Kirodimal Government General Hospital, Raigarh International Journal of Medical Research Professionals.
15. F. Ellis mckenzie, jeeraphat sirichaisinthop, r. Scott miller, robert a. Gasser jr, and chansuda wongsrichanalai dependence of malaria detection and species Diagnosis by microscopy on parasite density published in final edited form as *Am j trop med hyg.* 2003 october ; 69(4): 372–376..
16. Rella Zoleko Manego, Erik Koehne, Andrea Kreidenweiss<sup>1,2</sup>, Brice Nzigou Mombo, Bayode Romeo Adegbite, Lia Betty Dimessa Mbadanga, Malik Akinosho, Julian Matthewman, Ayola Akim Adegnika, Michael Ramharter and Ghyslain Mombo-Ngoma Description of Plasmodium falciparum infections in central Gabon demonstrating high parasite densities.
17. P. Chakraborty. Text Book of Medical Parasitology. Chapter 5. Plasmodium and Babesia. Plasmodium..
18. Flow Inc. Portland. Oregon. USA. Diamed Optimal Rapid Malaria Dip Stick Test. Kit Literature.
19. Becton Dickinson. Tropical Disease Diagnostics Becton Dickinson and Company. QBC Malaria Test. Kit Literature.
20. Jamshaid Iqbal et al, Department of Microbiology, Kuwait University. Comparison of two commercial assays with expert microscopy for Confirmation of symptomatically diagnosed malaria. Sept. 1999 to Mar. 2002. *Journal of CI. Micro*, Dec. 2002, p. 4675-4678, Vol. 40, No. 12.
21. Lowe BS et al, Kenyran Medical Research Institute, CRC Kilifi Unit, Kenya, 1996. *Trans R Soc. Trop Med Hyg* 1996 Jan-Feb; 90(1): 34-6.
22. Palmer et al, Handuras, 1998. *J. Clin. Microbiol.* 1998; 36(1): 103-6.
23. Eonul Asianetal, Turkey 2001. *Mem. Inst. Oswaldo Cruz* Vol. 96, No. 5, Rio de Janeiro, July 2001. Vol. 96(5): 683-686.
24. Baird JK et al, US naval medical research unit No. 2, San Francisco. *Am J Trop Med Hyg.* 1999 Feb; 60(2): 177-82.

- 25 Lema OE et al in 1999, in University of Nairobi, Kenya. Med. Trop. (Mars).2001;61(2):153-7.
- 26 Bradley i. Coleman, kristen m. Skillman, rays h. Y. Jiang, lauren m. Childs, Lindsey M. Altenhofen, markus ganter, yvette leung ilana goldowitz, björn f.c. kafsack, Matthias marti, manuel llinás, caroline o. Buckee, and manoj t. Duraisingh a *plasmodium falciparum* histone deacetylase regulates Antigenic variation and gametocyte conversion published in final edited form as: *Cell host microbe*. 2014 august 13; 16(2): 177–186. Doi:10.1016/j.chom.2014.06.014

**Address for correspondence:**

Mr. Vivek Trivedi Ph.D Scholar H. No 21-22 Bhairav Dham Colony Opp BSNL Office Sec. No 3 Hiran Magri Udaipur, Rajasthan . Pin 313002 India

E-mail: [trivedi\\_vivek123@yahoo.co.in](mailto:trivedi_vivek123@yahoo.co.in)